Shoulder Pain

Initial assessment

Careful history ('SOCRATES' for pain), vital signs
LOOK – asymmetry, muscle bulk, deformity
FEEL – check for heat, swelling, deformity, tenderness - from sterno-clavicular joint, all around shoulder joint, scapula, neck, upper back muscles
MOVE – both **active** and **passive** movements: flexion, extension, abduction, adduction, internal and external rotation; check **resisted abduction and external rotation**

RED FLAGS – discuss with consultant

- Any mass/swelling, possible tumour (bone/lung)
- Red skin, fever, systemic upset
- Hx trauma/seizure with loss of rotation and abnormal shape
- Trauma, pain and weakness
- Bilateral? Consider PMR / inflammatory arthritis

Is pain from Neck or Shoulder or Other?

- Check active neck movements (lateral flexion most important)
- Does this reproduce the pain?

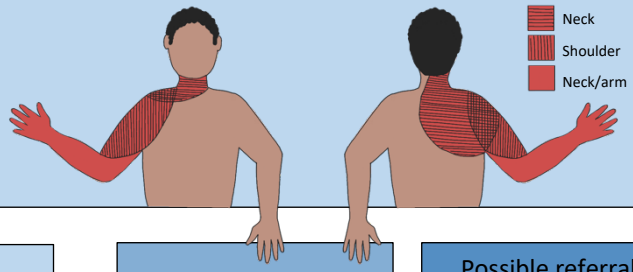

NECK

Common age 35y+

- Often produces pain round the back of shoulder or down arm
- Perform neuro examination of upper and lower limbs
- If neurological involvement, discuss with consultant
- Rest
- NSAIDs (topical/oral)/paracetamol
- Physiotherapy

SHOULDER

History of instability?

- Has your shoulder ever partly or completely come out of joint?
- Are you worried that your shoulder may dislocate or slip in the joint on sporting activities or certain movements?

YES → **Instability**
Physio if atraumatic → **Instability**
Traumatic dislocation
Ongoing symptoms
Atraumatic with failed physio

NO ↓

- Is the pain localised to the AC joint and associated with tenderness?
- Is there a positive scarf (cross arm) test?

YES → **AC Joint disease**
- Relative rest
- NSAIDs (topical/oral) /paracetamol

→ **AC Joint disease**
- If not improving

NO ↓

Reduced passive movements of the shoulder, especially passive external rotation?

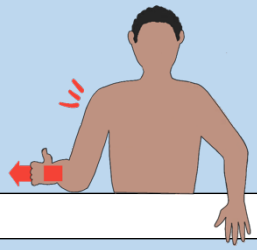

YES → **Glenohumeral joint disease**
frozen shoulder - common age 40-60; with diabetes
OA - common age 60+
Often patient complains of pain over the deltoid
- Xray to differentiate & to exclude serious pathology
- Relative rest, NSAIDs (topical/oral)/paracetamol

→ **Glenohumeral joint disease**
- Ongoing pain
- Considering injection

NO ↓

- Is there a painful arc of abduction?
- Is there pain on abduction with the thumb down, worse against resistance?

NB A history of trauma with loss of abduction in a younger patient = **RED FLAG!**

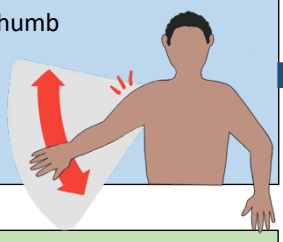

YES → **Rotator cuff disorder**
Tendinopathy, tears, osteophytes, bursitis
Often patient complains of pain over the deltoid
- Relative rest, modification of causative activity
- NSAIDs (topical/oral)/ paracetamol
- Physiotherapy

NB. USS/MRI is not helpful as symptoms do not relate to severity of pathology on imaging; often incidental findings

→ **Rotator cuff disorder**
- Not improving
- Considering corticosteroid injection

NB. Massive tears in patients >75 years are generally not reparable

NO ↓

Other cause of Neck or Arm pain

OPD MANAGEMENT

Possible referral to orthopedics – **discuss with consultant**